Approach to Unclassifiable Interstitial Lung Diseases

Kirk D. Jones, MD
UCSF Dept. of Pathology
kirk.jones@ucsf.edu

Classifying the Unclassifiable

Zen Koan?

What is the sound of one hand clapping?

What is the classification of the unclassifiable?

Early Exposure to the Problem

- Is this a difficult problem or is it one with a simple solution?
- Flow chart.

Why Classify at All?

- Classification of interstitial pneumonias allows for both prognostic stratification as well as determination of treatment.



Old School

- Since nothing works on UIP, let's just start with steroids, and if it works…great! And if it doesn't…no harm done!

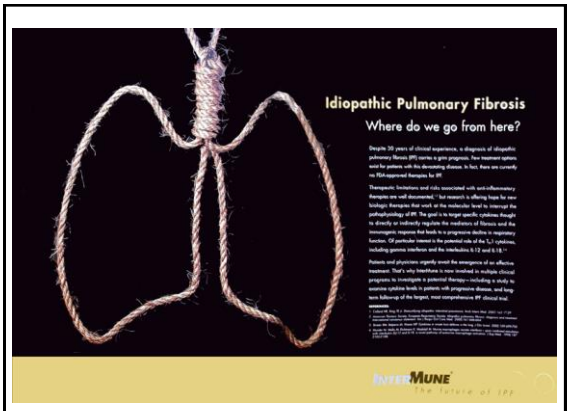

Significance of a UIP Diagnosis

- Don't treat with the usual agents!
  - Prednisone and azathioprine shown to be bad
  - PANTHER study
    - Increased deaths (8 vs. 1)
    - Increased hospitalization (23 vs. 7)
  - NAC vs placebo no difference
- Novel antifibrotics and TKI's
  - ASCEND trial
  - INPULSIS trial

What question is being asked?

- Is this a clinical or a pathologic question?
- The Gold Standard is CRaP
  - Clinical-Radiologic-Pathologic Multidisciplinary Discussion
- 2002 ATS/ERS Classification of IIP's
  - "subset of patients…that remain unclassifiable after extensive …examination."
  - Inadequate CRaP
  - Discrepant CRaP
  - Prior therapy resulted in altered appearance (pathology)
  - Variable patterns on pathology or radiology

Am J Respir Crit Care Med. 2002 Jan 15; 165(2): 277-304.PMID: 11790668.

TABLE 1. REVISED AMERICAN THORACIC SOCIETY/EUROPEAN RESPIRATORY SOCIETY CLASSIFICATION OF IDIOPATHIC INTERSTITIAL PNEUMONIAS: MULTIDISCIPLINARY DIAGNOSES

Major idiopathic interstitial pneumonias
- Idiopathic pulmonary fibrosis
- Idiopathic nonspecific interstitial pneumonia
- Respiratory bronchiolitis–interstitial lung disease
- Desquamative interstitial pneumonia
- Cryptogenic organizing pneumonia
- Acute interstitial pneumonia

Rare idiopathic interstitial pneumonias
- Idiopathic lymphoid interstitial pneumonia
- Idiopathic pleuroparenchymal fibroelastosis

Unclassifiable idiopathic interstitial pneumonias*

*Causes of unclassifiable idiopathic interstitial pneumonia include (*1*) inadequate clinical, radiologic, or pathologic data and (*2*) major discordance between clinical, radiologic, and pathologic findings that may occur in the following situations: (*a*) previous therapy resulting in substantial alteration of radiologic or histologic findings (e.g., biopsy of desquamative interstitial pneumonia after steroid therapy, which shows only residual nonspecific interstitial pneumonia [153]); (*b*) new entity, or unusual variant of recognized entity, not adequately characterized by the current American Thoracic Society/European Respiratory Society classification (e.g., variant of organizing pneumonia with supervening fibrosis) (*79*); and (*c*) multiple high-resolution computed tomography and/or pathologic patterns that may be encountered in patients with idiopathic interstitial pneumonia.

Am J Respir Crit Care Med. 2013 Sep 15; 188(6): 733-48. PMID: 24032382.

2013 Update of IIP Classification

- Cases that are "unclassifiable" in terms of overlap of histologic patterns often…CVD…or drug-induced, rather than being idiopathic on MDD.
- If ILD is difficult…to classify, management should be based on the most probable diagnosis after MDD

Am J Respir Crit Care Med. 2013 Sep 15; 188(6): 733-48. PMID: 24032382.

Clues to Other Diagnoses

- Hypersensitivity pneumonia
  - Granulomas or giant cells
  - Bronchiolocentric fibrosis
  - Bronchiolocentric fibroblast foci
  - Characteristic CT features (mosaicism or head cheese)

Ohtani Y, et al. Thorax. 2005 Aug; 60(8): 665-71. PMID: 16061708.
Takemura T, et al. Histopathology. 2012 Dec; 61(6): 1026-35. PMID: 22882269.
Trahan S, et al. Chest. 2008 Jul; 134(1): 126-32. PMID: 18339775.

Clues to Other Diagnoses

- Autoimmune connective tissue disease
  - Prominent lymphoid aggregates
  - Overlapping UIP and NSIP fibrosis
  - Fewer or smaller fibroblast foci
  - Involvement of pleura, bronchioles, or vessels
  - Characteristic CT features

Cipriani NA, et al. Arch Pathol Lab Med. 2012Oct; 136(10): 1253-8. PMID: 23020731.
Urisman A, et al. SeminRespir Crit Care Med. 2014 Apr; 35(2): 201-12. PMID: 24668535.

The Clinical View

- Prevalence and prognosis of unclassifiable interstitial lung disease
  - Around 10% of the UCSF cohort (132 of 1370).
    - 50% - too frail for biopsy
    - 8% - insufficient tissue on biopsy
    - 8% - declined biopsy

    } 2/3 have biopsy-related issues
    - 9% - mild or stable disease
    - 18% - discrepant CRaP

Ryerson CJ, et al. Eur Respir J. 2013 Sep; 42(3): 750-7. PMID: 23222877.

If CRaP says unclassifiable

- When MDD discussion result is unclassifiable – what does the pathology show?
  - UIP – 22%
  - Unclassifiable fibrosis – 17%
  - fNSIP – 17%
  - Non-diagnostic biopsy – 15%
  - OP – 6%
  - All less than 5%: DAD, bronchiolocentric fibrosis, normal, DIP, emphysema, RB, granulomas, cNSIP, follicular bronchiolitis (n=78)

When Pathology "Unclassifiable" what is MDD result?

- Unclassifiable – 33%
- UIP/IPF – 19%
- HP – 17%
- Connective tissue disease – 11%
- NSIP – 6%
- Pending – 6%
- MAC – 3%
- Smoking – 3%
- Sarcoid – 3%

Ryerson Results

- The pathologic appearance (and radiologic appearance) is useful in cases where MDD is unclassifiable
  - Hazard ratio when diff. diagnosis includes IPF is 5.49
- When patient is too old or frail for a biopsy, the hazard ratio is 3.22

Eur Respir J. 2013 Sep; 42(3): 750-7. PMID: 23222877.

Case 1

- 65-year-old man with dyspnea and cough
- Started during kitchen remodel
- Associated muscle weakness
- CT scan: Reticulation and traction bronchiectasis with regions of subpleural sparing. Findings are consistent with fibrotic NSIP.

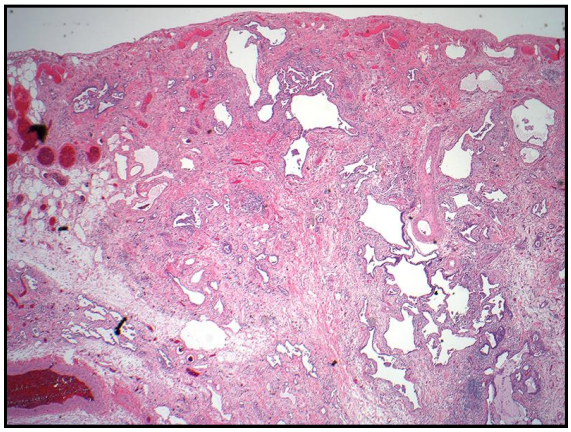

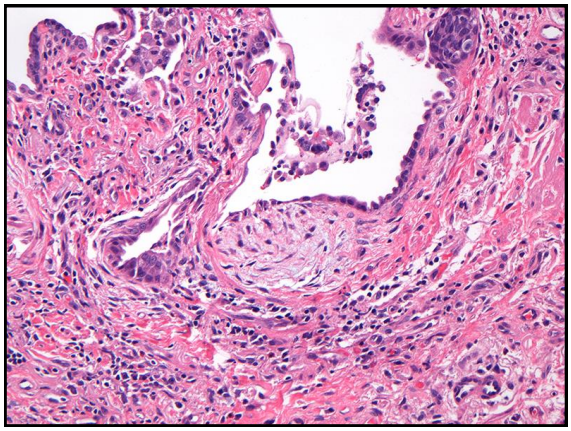

Case 1 - Unclassifiable

- Advanced interstitial fibrosis
  - Honeycombing only (with fibroplasia)
  - Leaning toward UIP, but a little unusual.
- MDD is unclassifiable, but favor autoimmune myositis base on clinical features.

Case 2

- 74 year old man with shortness of breath increasing over last 14 months.

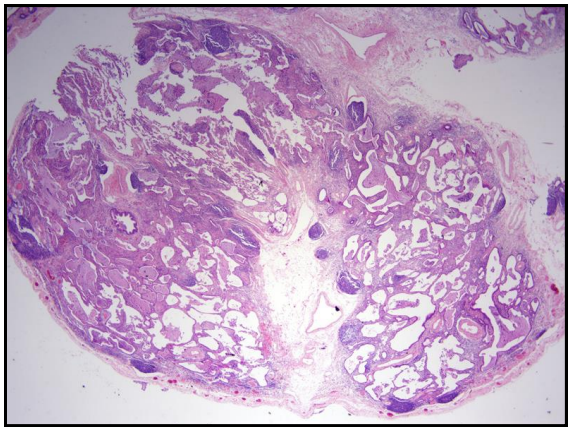

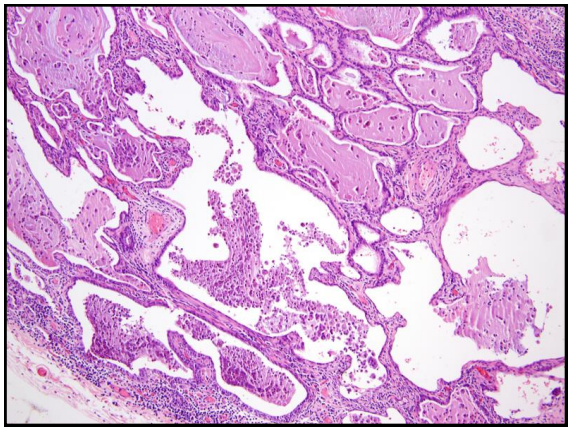

Case 2

- Called fibrotic NSIP with prominent lymphoid aggregates.
- Question of whether had honeycombing.

Case 2 - Continued

- Patient had history of prostatic hypertrophy and urine retention.
- On nitrofurantoin for 2 years.
  - Stealth drug (post-coital UTI's, BPH)
- www.pneumotox.com

Case 3 – MDD Extreme

- 62-year-old man with severe pulmonary fibrosis
- Prior biopsy with UIP pattern
- Now undergoing bilateral lung transplant

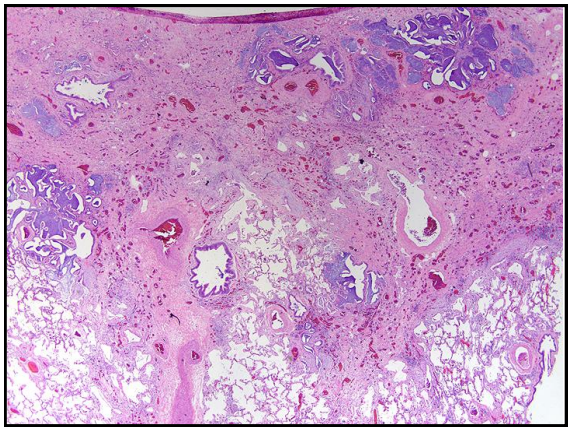

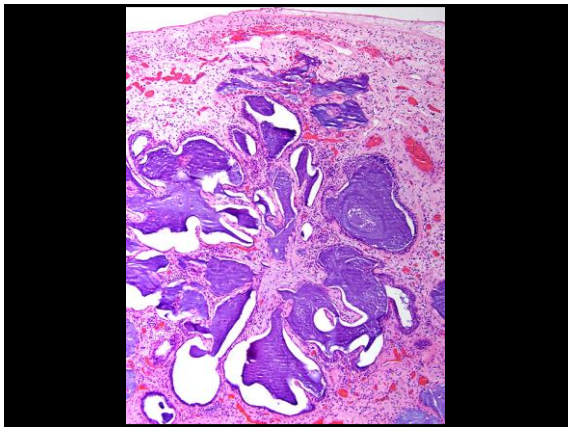

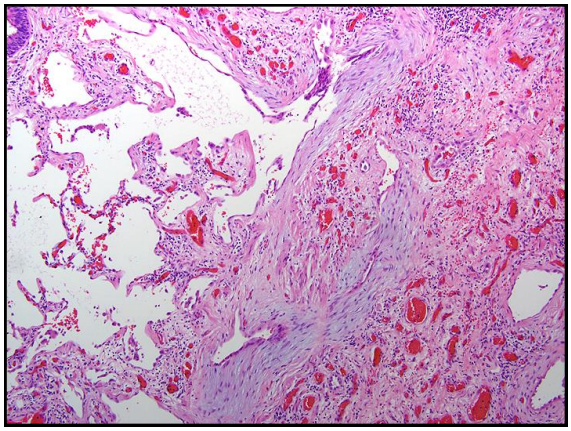

Pathologic Pattern

- Usual interstitial fibrosis
  - Marked fibrosis with honeycombing
  - Patchy involvement of lung
  - Fibroblast foci present
  - ?Features suggesting alternate diagnosis?

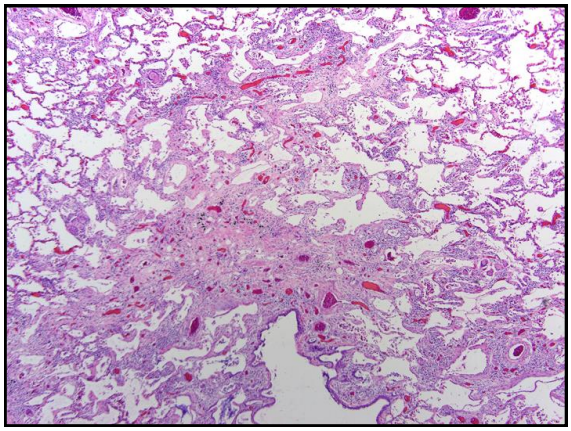

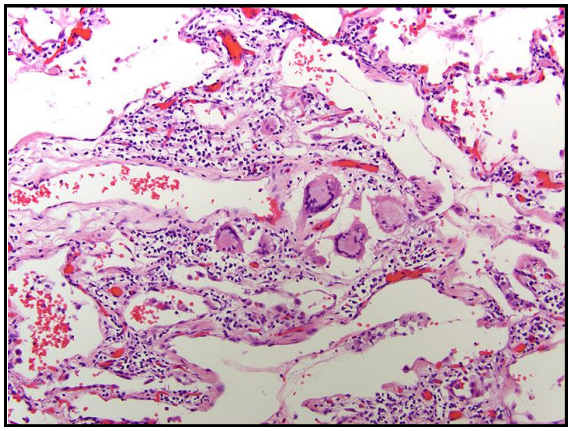

Pathologic Diagnosis

- Interstitial fibrosis, UIP pattern, with bronchiolocentric fibrosis and chronic inflammation, and poorly formed granulomas.
- Most consistent with chronic hypersensitivity pneumonia.

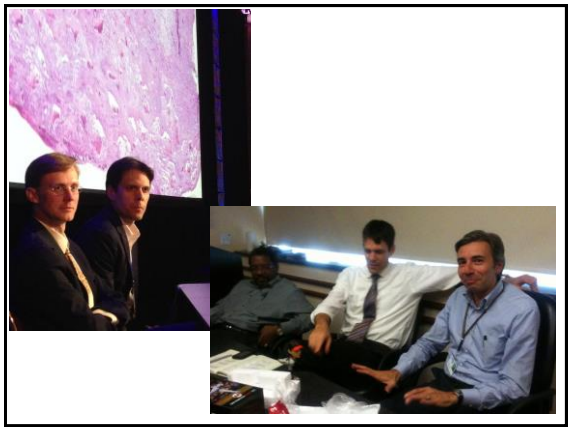

Final Diagnosis

- Familial Interstitial Fibrosis
  - Telomerase mutation (TERT gene)
- With superimposed hypersensitivity pneumonia

IPF is a Telomeropathy

- Familial cases of IPF linked with telomerase mutations (e.g. TERT, TERC)
  - Premature gray hair, bone marrow failure, cirrhosis, macrocytic anemia, early menopause
- Familial cases of interstitial fibrosis show a wide variety of pathologic patterns
  - Differening injuries resulting in premature damage
- Sporadic IPF cases tend to have short telomeres

Holohan B, et al. J Cell Biol. 2014 May 12; 205(3): 289-99. PMID: 24821837.
Snetselaar R, et al. Chest. 2015 May 14. PMID:25973743.

Conclusions

- Unclassifiable is not equal to uninformative
  - Are you honest or famous?
  - Give the information you have
    - Small biopsy or bad biopsy
    - Good biopsy with a differential diagnosis
- Use histologic clues combined with MDD to arrive at a best-guess diagnosis for patient treatment.